DOI: 10.14260/jemds/2014/2658

ORIGINAL ARTICLE

COMPUTED TOMOGRAPHY GUIDED FINE NEEDLE ASPIRATION CYTOLOGY OF MASS LESIONS OF LUNG: A STUDY IN CENTRAL INDIA

Vivek Gupta[1], Jyoti Valecha[2], Jharna Mishra[3], Roshan Chanchlani[4]

HOW TO CITE THIS ARTICLE:
Vivek Gupta, Jyoti Valecha, Jharna Mishra, Roshan Chanchlani. "Computed Tomography Guided Fine Needle Aspiration Cytology of Mass Lesions of Lung: A Study in Central India". Journal of Evolution of Medical and Dental Sciences 2014; Vol. 3, Issue 21, May 26; Page: 5742-5747, DOI: 10.14260/jemds/2014/2658

ABSTRACT: BACKGROUND: CT guided FNAC of lesions of the lungs and the mediastinum is widely practiced in several institutions where the facilities of standard imaging techniques and cytopathology are available. This procedure provides a safe, rapid, and accurate diagnosis in patients having thoracic mass lesions. **MATERIAL AND METHODS:** The study was conducted in the department of Radiology, Chirayu medical college and hospital, Bhopal during the period of Jan 2012 – Mar 2014. A total no. of 132 patients were selected who underwent CT-guided transthoracic fine needle aspiration from pulmonary mass lesions. A detailed clinical history was obtained. FNAC was performed in the pulmonary lesions using a 22 or 23 gauge disposable lumbar puncture needle after obtaining proper informed consent. **RESULTS:** out of total 132 study subjects neoplastic lesions were found in 98(74.2%) cases whereas 34(25.8%) had non-neoplastic lesions. Squamous cell carcinoma was the most common neoplastic lesion found in 54(40.9%) cases, 45(34.1%) males and 09(6.8%) females followed by adenocarcinoma found in 22(16.6)cases, 16(12.1%) males and 6(04.4) females. **CONCLUSION:** CT guided FNAC provides very early diagnosis and exact sub-classification of various lung tumors on the basis of cytomorphology. The early and accurate diagnosis obtained by CT-guided FNAC helps to formulate immediate, effective management of thoracic mass lesions.

KEYWORDS: Computed tomography, FNAC, Lung lesions.

INTRODUCTION: Percutaneous, transthoracic fine needle aspiration cytology (FNAC) is a well-established diagnostic method used in the cytological evaluation of thoracic mass lesions for the last three decades. Nowadays, computed tomography (CT)-guided FNAC of lesions of the lungs and the mediastinum is widely practiced in several institutions where the facilities of standard imaging techniques and cytopathology are available. This procedure provides a safe, rapid, and accurate diagnosis in patients having thoracic mass lesions.[1, 2, 3]

Recognition of the high accuracy rate of FNAC along with the simpler methods to treat its complications like pneumothorax has increased its popularity among clinicians, radiologists and pathologists.[4-6]

The special advantage of FNAC includes detection of those tumor types like small cell carcinoma, lymphomas more appropriately treated by chemotherapy rather than surgery. Numerous literatures supported that CT-guided FNAC is an accurate and sensitive way of diagnosing malignancy of the thorax.[7]

This procedure is almost minimum painful non-operative procedure as compared with biopsy for diagnosis of pulmonary mass, outweighs the single major rare complication of pneumothorax.[8]

MATERIAL AND METHODS: The study was conducted in the department of Radiology, Chirayu medical college and hospital, Bhopal during the period of Jan 2012 – Mar 2014. A total no. of 132

DOI: 10.14260/jemds/2014/2658

patients were selected who underwent CT-guided transthoracic fine needle aspiration from pulmonary mass lesions. The inclusion criteria of this study were persons with mass lesion(s) in the lung clinically suspected to be pulmonary neoplasm and with sputum samples negative for acid-fast bacilli (AFB).

A detailed clinical history including the demographic data, clinical history, personal history including smoking habit, contact history of tuberculosis, etc. was obtained. FNAC was performed in the pulmonary lesions using a 22 or 23 gauge disposable lumbar puncture needle after obtaining proper informed consent. Patients with arteriovenous malformation, aneurysm, pulmonary hypertension or histories of bleeding disorder were not included.

The smears were attained with the Papanicolaou stain after wet fixation and May-Grunwald-Giemsa (MGG) stain following dry fixation. The patients were kept in the radiology department for follow-up for a period of 2 hours after fine needle aspiration to keep track of any complication. A repeat CT scan was performed if indicated in case any complication developed.

RESULTS: In the present study, out of total 132 study subjects 98(74.2%) were male and 34(25.8%) were female. Maximum subjects belong to the age group of 51 to 60 years. Mean age of the subjects was 44±2.6. Distribution of the study subjects according to the age group is shown in table no. 1.

Cough was the most common symptom present in 70.4% cases, followed by weight loss (49.2%). Radiologically, solitary mass lesion was present in 64.5% cases, more than one lesion in 7.8% cases and collapse/consolidation in 27.5% cases. Distribution of the study subjects according to the presenting symptoms is shown in table no. 2.

In our study most of the lesions involved right lung 77(58.3%) and left lung involved in 55(41.6%) cases. Distribution of the lesions according to the site is shown in table no. 3.

In present study, out of total 132 study subjects neoplastic lesions (Fig. 1, 2, 3) were found in 98(74.2%) cases whereas 34(25.8%) had non-neoplastic lesions (Fig. 4, 5) Squamous cell carcinoma was the most common neoplastic lesion found in 54(40.9%) cases, 45(34.1%) males and 09(6.8%) females followed by adenocarcinoma found in 22 (16.6)cases, 16 (12.1%) males and 6 (04.4) females. Most common non-neoplastic lesion in the study subjects was chronic inflammation found in 12 (09.0%) cases, 5(03.7%) males and 5(03.7%) females followed by abscess/Suppurative inflammation which was found in 05(03.7%) male cases, Distribution of neoplastic lesions according to their types and frequency in both sexes is shown in table no. 4.

DISCUSSION: The main objective of the CT guided FNAC is to diagnose malignancy although it can be used for differential diagnosis of some benign neoplasms and infections as kochs.[9] In our study neoplastic disorders in male was 80(60.6%) and female was 21(15.9%) which corresponds to the other studies done by Alam et al and Syed et al.[10,11]

In our study most of the lesions involved right lung 77(58.3%) and left lung involvement was seen in (41.6%) cases, which corresponds to the study done by Syed Ahmed in 2009 in Chittagong.[11] Out of 132 cases 98 were neoplastic and 31 were non-neoplastic which is slightly higher than the study conducted by Syed Ahmed and JH Stanley.[11,12]

In case of neoplastic lesions, most of the neoplasms 54(40.9%) were squamous cell carcinoma followed by adenocarcinoma 22 (16.6%) which correlates with the WHO study.[13] Though pneumothorax was most common complication of other studies, but we did not found any case in our

DOI: 10.14260/jemds/2014/2658

study. The overall rate of complications (2.4%) in our study was also remarkably less than other series where the range varied from 6% to 50%.[14, 15] In our study, mild hemorrhage from peri-lesional area in one case and chest pain in two cases was found and which could be managed conservatively.

In our study, CT guided FNAC showed almost perfect agreement with histological diagnosis in comparison to radiological opinion. So FNAC was found to be highly accurate (95%) in diagnosis of lung mass as almost similar shown by previous studies.

CONCLUSION: CT guided fine needle aspiration cytology (FNAC) is a simple and safe procedure with high diagnostic accuracy for the diagnosis and cell typing of Lung cancer. It provides very early diagnosis and exact sub-classification of various lung tumors on the basis of cytomorphology. Benign non-neoplastic lesions like tuberculosis can also be diagnosed with certainty by this technique. The early and accurate diagnosis obtained by CT-guided FNAC helps to formulate immediate, effective management of thoracic mass lesions.

Age group in years	Male	Female	Total
31-40	04(03.0)	3(02.2)	07(05.2)
41-50	17(12.8)	9(06.8)	26(19.6)
51-60	44(33.3)	11(08.3)	55(41.6)
61-70	33(25.0)	11(08.9)	44(36.3)
Total	**98(74.2)**	**34(25.8)**	**132(100)**

Table no. 1: Distribution of the study subjects according to the age group

Symptoms	Number of cases(n=132)	Percentage
Chest pain	64	48.4
Cough	93	70.4
Weight loss	65	49.2
Fever	34	25.7
Hemoptysis	26	19.6

Table no. 2: Distribution of the subjects according to the presenting symptoms

*Multiple responses

Site	Squamous cell carcinoma n (%)	Adeno carcinoma n (%)	Other neoplastic disorders n (%)	Total n (%)
Right	37(28.0)	15(11.3)	25(18.9)	77(58.3)
Left	29(21.9)	13(9.8)	13(9.8)	55(41.6)
Total	**66(48.9)**	**28(21.1)**	**38(28.7)**	**132(100)**

Table no. 3: Distribution of the lesions according to site

DOI: 10.14260/jemds/2014/2658

Type of lesion	Male (%)	Female (%)	Total (%)
Neoplastic lesions			
1. Squamous cell carcinoma	45(34.1)	9(06.8)	54(40.9)
2. Adeno carcinoma	16(12.1)	6(04.4)	22(16.6)
3. Non-Hodgkin's lymphoma	05(03.7)	2(01.5)	07(05.3)
4. Large cell carcinoma	4(03.0)	2(01.5)	06(04.5)
5. Poorly differentiated carcinoma	6(04.4)	1(0.07)	07(05.3)
6. Malignant mesothelioma	2(01.5)	1(0.07)	03(02.2)
7. Small cell carcinoma	1(0.07)	0(00)	01(0.7)
8. Hamartoma	1(0.07)	0(00)	01(0.7)
Non-neoplastic lesions			
1. Chronic inflammation	7(05.3)	5(03.7)	12(09.0)
2. Abscess/Suppurative inflammation	5(03.7)	0(00)	05(03.7)
3. Granulomatous inflammation	4(03.0)	4(03.0)	08(06.0)
4. Pneumonic consolidation	2(01.5)	3(02.2)	05(03.7)
Total	**98(74.2)**	**34(25.8)**	**132(100)**

Table no. 4: Distribution of lesions according to type, frequency and sex

REFERENCES:

1. Stewart CJ, Stewart IS. Immediate assessment of fine needle aspiration cytology of lung. J Clin Pathol 1996; 49:839-43.
2. Salazar AM, Westcott JL. The role of transthoracic needle biopsy for the diagnosis and staging of lung cancer. Clin Chest Med 1993; 14:99-110.
3. Sanders C. Transthoracic needle aspiration. Clin Chest Med 1992; 13:1-16.
4. Byrd RP, Jr, Fields-OC, Roy TM. Delayed chest radiographs and the diagnosis of pneumothorax following CT-guided fine needle aspiration of pulmonary lesions. Respir Med. 1999; 93:379–81.
5. Santambrogio L, Nosotti M, Bellaviti N, Pavoni G, Radice F, Caputo V. CT-guided fine needle aspiration cytology of solitary pulmonary nodules: A prospective, randomized study of immediate cytologic evaluation. Chest. 1997; 112:423–5.
6. Westcott JL, Rao N, Colley DP. Transthoracic needle biopsy of small pulmonary nodules. Radiology. 1997; 202:97–103.
7. Mullan CP, Kelly B. E, Ellis PK, Hughes S, Anderson N, Mc Cluggage WG. CT guided fine-needle aspiration of lung nodules: effect on outcome of using coaxial technique and immediate cytological evaluation.
8. Cox JE, Chiles C, McManus CM, Aquino SL, Choplin RH. Transthoracic needle aspiration biopsy: variables that affect risk of pneumothorax. Radiology. 1999 Jul; 212(1):165–168.
9. Madan M, Bannur H. Evaluation of FNAC in lung diseases. Turk J Path. 2010; 26: 1-6.
10. Alam AMMS, Kabir MF, Anwar S et al. Distribution pattern and probable etiological factors of cancer in Chittagong an eight years hospital based study. JCMCTA 1999; 10 (S4): 3-31.

DOI: 10.14260/jemds/2014/2658

11. Syed A, M Shahab Uddin Ahamad. Computed tomography guided fine needle aspiration cytology of lung lesions. A study of 162 cases. JMCTA 2009;20(1): 50-52.
12. Stanley J H, G D Fish, Androle et al. Lung lesions: Cytologic diagnosis by fine needle biopsy. Radiology: 1987; 162: 389-391.
13. Hussain A N. Kumar V. The lung in; Kumar V, Abbas A K, Fausto N. Pathologic basis of diseases. 2005: Elsevier Saunders. 711-772.
14. Thamboo TP, Wang SC, Nilsson B, Rajwanshi A, Salto-Tellez M. Audit of transthoracic fine needle aspiration of the lung: Cytological sub classification of bronchogenic carcinomas and diagnosis of tuberculosis. Singapore Med J. 2002; 43:570–5.
15. Adhyay A, Laha R, Das TK, Sen S, Mangal S, Mitra PK. CT guided fine needle aspiration cytology of thoracic mass lesions: A prospective study of immediate cytological evaluation. Indian J Pathol Microbiol. 2007; 50:51–5.

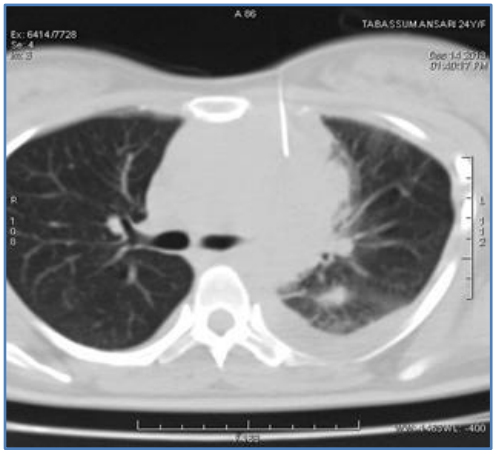

Figure 1: CT guided FNAC in Non Hodgkins lymphoma



Figure 2: CT guided FNAC in Squamous cell carcinoma

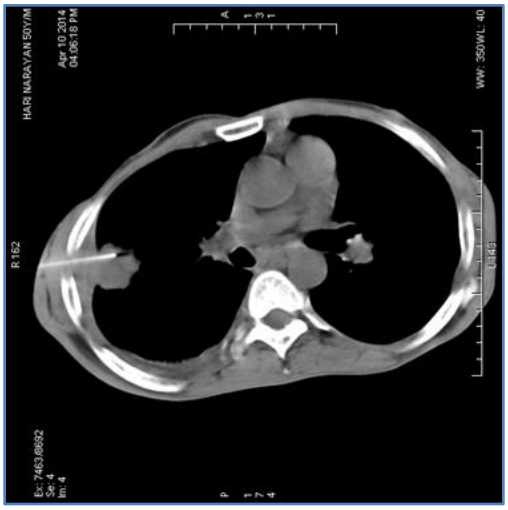

Figure 3: CT guided FNAC in Adenocarcinoma



Figure 4: CT guided FNAC in Non-specific granulomatous lesion

DOI: 10.14260/jemds/2014/2658

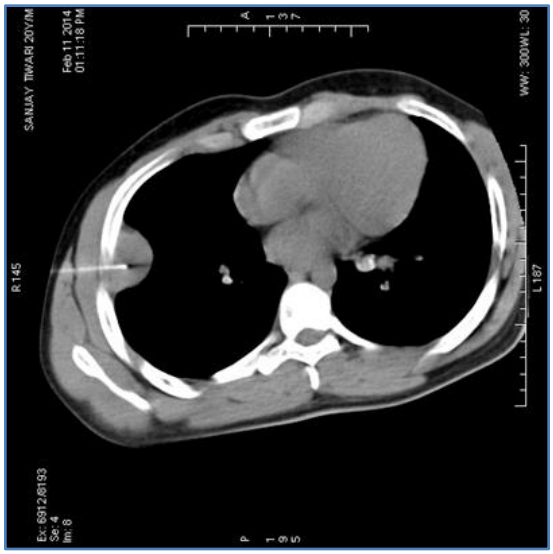

Figure 5: CT guided FNAC in tuberculosis

AUTHORS:

1. Vivek Gupta
2. Jyoti Valecha
3. Jharna Mishra
4. Roshan Chanchlani

PARTICULARS OF CONTRIBUTORS:

1. Assistant Professor, Department of Radiology, Chirayu Medical College and Hospital, Bhopal.
2. Assistant Professor, Department of Radiology, Chirayu Medical College and Hospital, Bhopal.
3. Assistant Professor, Department of Radiology, Chirayu Medical College and Hospital, Bhopal.
4. Associate Professor, Department of Surgery, Chirayu Medical College and Hospital, Bhopal.

NAME ADDRESS EMAIL ID OF THE CORRESPONDING AUTHOR:

Dr. Roshan Chanchlani,
1/6 - Idgah Kothi, Doctors Enclave,
Near Filter Plant, Idgah Hills,
Bhopal – 462001, M. P.
E-mail: roshanchanchlani@gmail.com

Date of Submission: 10/05/2014.
Date of Peer Review: 12/05/2014.
Date of Acceptance: 16/05/2014.
Date of Publishing: 23/05/2014.